

Molecular Subgroups of Small (pT1) Breast Carcinomas Belonging Exclusively to the Ductal Infiltrating Variety

JOSÉ SCHNEIDER^{1,2}, ARMANDO TEJERINA¹, CLEMENTE PEREA¹, RAÚL LUCAS¹ and JAIME SÁNCHEZ^{1,3}

¹Centro de Patología de la Mama, Madrid;

²Universidad Rey Juan Carlos, Facultad de Ciencias de la Salud, Alcorcón, Madrid;

³Universidad de Alcalá, Alcalá de Henares, Madrid, Spain

Abstract. *Background:* The use of microarray technology has resulted in a new classification of breast cancer according to gene expression profiles. None of the reports published so far using this new classification has stratified the studied tumors by histology or size. *Materials and Methods:* This study was restricted to the ductal infiltrating variety only, and to pT1 size using the immunohistochemical markers estrogen receptor (ER), progesterone receptor (PR), HER2 and cytokeratin 5/6. ER+ and/or PR+, HER2- tumors were termed "luminal A"; ER+ and/or PR+, HER2+ "luminal B"; triple-negative, CK 5/6+ and/or HER1+ "basal-like"; with an additional category for ER-, PR-, HER2+ tumors termed HER2, and a final group of unclassified ones, negative for all five markers. *Results:* Out of 346 tumors, 251 (72.5%) were luminal A, 45 (13%) were "triple-negative" ("basal"-like), 20 (5.8%) were luminal B, and 30 (8.7%) were HER2. Luminal A, "triple-negative" ("basal"-like), and HER2-expressing tumors (luminal B + HER2) showed significantly different associations with histological and nuclear grade, mutant p53 expression and Ki67 labelling index. *Conclusion:* Studies of the other, less frequent histological varieties of breast cancer, stratifying by tumor size, are mandatory to disclose which precise gene-expression pattern defines similar subgroups.

The pioneering work of Perou *et al.* (1) and van't Veer *et al.* (2) using microarray technology has resulted in an attempt to reclassify breast tumors according to specific patterns of gene expression. The most widely accepted such classification identifies five different types of breast cancer, named "luminal A" (with high expression of the estrogen alpha receptor (ER α) and related genes), "luminal B" (still expressing the estrogen alpha receptor, but at lower levels), "basal" (expressing genes

characteristic of myoepithelial cells, most notably cytokeratins (CK) 5/6 and 17), "HER2-expressing", and finally "normal-breast-like" tumors (although it is debated whether this last type is real, or the result of poor tissue sampling or defective processing (3)). A simplified version of this classification, using routinely-employed immunohistochemical markers as surrogates for the more complicated genomic studies has been proposed by the same group having published the first microarray study (4). Following this version, ER+ and/or progesterone receptor (PR)+, HER2- tumors are termed "luminal A"; ER+ and/or PR+, HER2+ "luminal B"; triple-negative, CK 5/6+ and/or HER1+ "basal-like"; with an additional category for ER-, PR-, HER2+ tumors termed HER2, and a final group of unclassified ones, negative for all five markers. These different molecular subclasses of breast cancer, according to either classification, carry a different prognosis, and this difference is especially marked when the "luminal A" subtype, with the best inherent prognosis, is compared to the "basal" and HER2-expressing subtypes, presenting the worst prognosis. The relative distribution within a given population of the molecular subclasses, finally, may account, at least in part, for the differences in prognosis of breast cancer observed between women belonging to distinct racial groups, such as African-American and Japanese (4).

Surprisingly, the above-cited initial reports by Perou *et al.* (1) and van't Veer *et al.* (2) did not take into account differences in histology between the tumors studied by them, when it is quite obvious that histological subtypes of breast cancer have markedly different gene expression patterns *ab initio*. So, lobular infiltrating carcinomas extremely rarely express the HER2 oncogene and mutant p53, but in spite of this, their prognosis is very similar to ductal infiltrating carcinomas. Conversely, medullary carcinomas very frequently express the HER2 oncogene, but their prognosis, stage for stage, is much better than the aforementioned types. Thus, the relative proportion of these histological subtypes, or of the more rare ones, may have influenced at least to some extent the results of these studies, and of all subsequent ones not substratifying by histology. Moreover, although it is now

Correspondence to: Prof. J. Schneider, Centro de Patología de la Mama, Calle Abascal 40. 28003 Madrid, Spain. e-mail: jose.schneider@urjc.es

Key Words: Breast cancer, luminal, basal.

generally accepted that the origin of cancer is monoclonal, it is also recognised that, as tumor growth advances, subclones with distinct characteristics may emerge, defining the final behavior of the tumor. Therefore, tumor size may also influence to some extent the final gene expression pattern of any given tumor, and this may differ from that of the initial tumorigenic clone.

With this in mind, the present study was restricted to the most frequent histological type of breast cancer, namely ductal infiltrating carcinoma, and within it to unifocal pT1 tumors, with a diameter of 2 cm or less of the surgical specimen, which are the ones most likely to reflect the characteristics of the original clone giving rise to the tumor.

Materials and Methods

Between January 1993 and December 2006, 346 unifocal ductal infiltrating carcinomas with a diameter of 2 cm or less on the surgical specimen (pT1) were operated upon at Centro de Patología de la Mama, Madrid, Spain. They were all initially diagnosed by the same pathologist, and the immunohistochemistry was also carried out by the same two technicians and interpreted by the same pathologist. By means of immunohistochemistry, hormone-receptor (ER & PR), HER2, mutant p53 and Ki67 expression was studied in all tumors. The immunohistochemical technique has been described extensively elsewhere (5, 6) and was the same throughout the series. It should be emphasized that the monoclonal antibody employed for ER detection (NCL-ER-6F11) selectively recognizes the alpha isoform of the receptor, a fact which is important considering that, according to the genetic studies cited in the Introduction, expression of ER alpha is the hallmark of "luminal"-type breast carcinomas. Additionally, CK 5/6 expression was studied in all "triple-negative" (ER-, PR-, HER2-) tumors, as well as in the same number of randomly chosen "non-basal" controls, using the DakoCytomation D5/16 B4 monoclonal antibody (DakoCytomation, Glostrup, Denmark) at 1:50 dilution, after heat-induced epitope retrieval, as specified by the manufacturers. The specimens were considered positive for CK 5/6, when more than 10% of the tumor cells showed specific staining (Figure 1). Myoepithelial reactive cells of normal breast tissue within the sections served as positive internal control (Figure 2).

Other variables considered in the final statistical analysis were the histological and nuclear grade of the tumors, tumor size and the presence or absence of axillary nodal metastasis.

The statistical analysis between qualitative variables was carried out by means of contingency tables and the Chi-square test, as well as by means of Spearman's rank correlation test, in order to obtain an "r" value indicative of the strength of the correlation between the different tested variables. The GraphPad Prism biomedical statistical package (GraphPad Software, Inc., San Diego, CA, USA) was used. Values were considered significant when *p* was <0.05.

Results

Tumor size distribution was 6 T1a, 88 T1b, 252 T1c and axillary nodal metastasis was present in 99 out of 346 cases (28.6%).

Table I. Comparison of the different molecular subtypes of pT1 ductal invasive breast carcinomas according to their correlation with clinical and biological features.

	Luminal A		HER2-expressing		"basal" (triple-negative)	
	r	p-value	r	p-value	r	p-value
size ≤ >10 mm	-0.04	0.45	0.03	0.49	0.1	0.06
nodal invasion	0.01	0.82	0.005	0.42	0.03	0.50
histological grade 3	-0.15	0.004*	0.15	0.004*	0.045	0.10
nuclear grade 3	-0.40	<0.001*	0.24	<0.001*	0.29	<0.001*
Ki67 >20%	-0.45	<0.001*	0.33	<0.001*	0.30	<0.001*
p53	-0.45	<0.001*	0.48	<0.001*	0.20	<0.001*

*=significant values.

According to the simplified classification of Carey *et al.* (4), out of 346 tumors, 251 (72.5%) corresponded to the luminal A type, 45 (13%) were "triple-negative" ("basal"-like), 20 (5.8%) expressed both the ER and the HER2 oncogene (luminal B), and finally 30 (8.7%) expressed the HER2 oncogene, but neither the ER, nor the PR (HER2 tumors). All tumors expressing the PR also expressed the ER. During the statistical workup it became evident that both HER2-expressing groups (luminal B and HER2) showed identical correlations with all tested biological and clinical parameters, and were thus included into a single group of HER2-expressing tumors, regardless of their hormone-receptor status.

When comparing luminal A tumors to the rest, they showed significantly fewer high histological and nuclear grade (*r*=-0.15, *p*=0.004 and *r*=-0.40, *p*<0.001, respectively), mutant p53 expression (*r*=-0.45, *p*<0.001) and a Ki67 labelling index above 20% (*r*=-0.42, *p*<0.001). Conversely, when triple-negative, "basal"-like tumors were compared to the rest, an almost specular image was obtained, since a highly significant number of them showed a high nuclear grade (*r*=0.29, *p*<0.0001), mutant p53 expression (*r*=0.20, *p*=0.0001) and a Ki67 labelling index above 20% (*r*=0.30, *p*<0.0001). Very similar results were obtained when comparing the unified group of HER2-expressing tumors to the rest whereas there were no differences between "basal" and the unified group of HER2-expressing tumors (Table I).

Interestingly, the highest proportion of mutant p53 expression was registered among "pure" HER2 tumors, without concomitant hormone receptor expression (18/30, 60%), followed by "basal" and luminal B tumors (both 35%) and the luminal A ones (6%).

None of the studied subgroups showed any correlation whatsoever with axillary nodal invasion. After immunohistochemical labelling with the anti-CK 5/6 antibody, 15 out of the 45 "basal" tumors (33.3%) showed some degree of specific

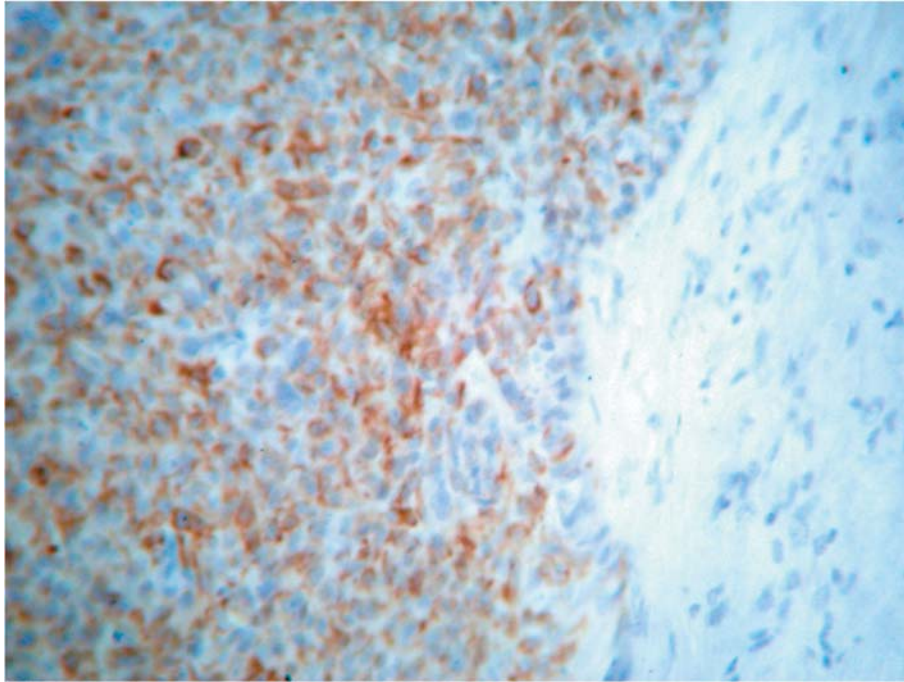


Figure 1. Immunohistochemical detection of Cytokeratin 5/6 in breast cancer. Intense reaction in most tumor cells, as opposed to surrounding stroma. Immunoperoxidase x250.

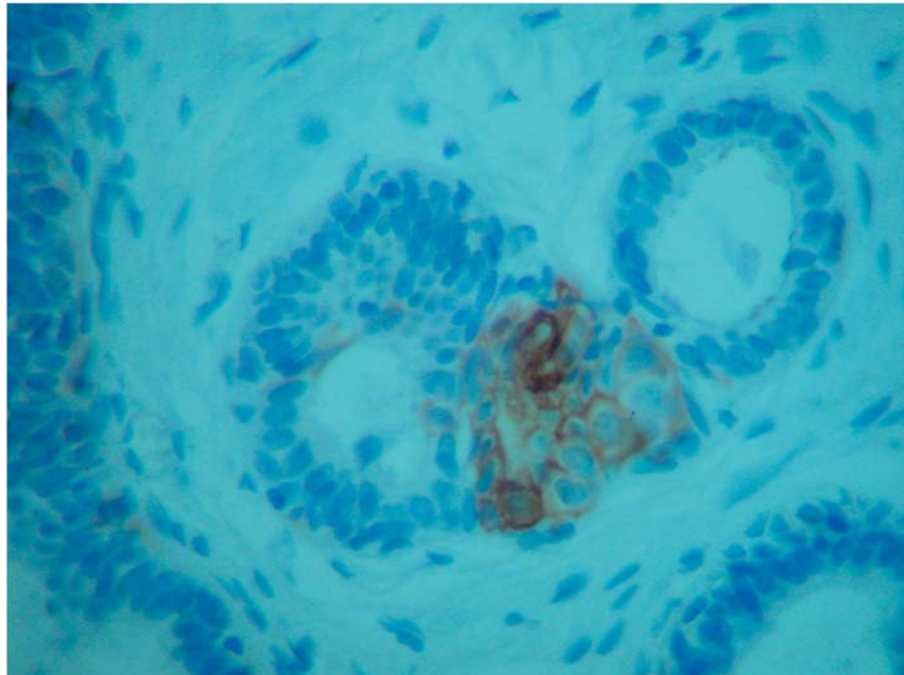


Figure 2. Immunohistochemical detection of Cytokeratin 5/6 in myoepithelial cells of normal breast ducts. Immunoperoxidase x400.

staining versus 9 out of 44 (20.5%) in the control group of randomly chosen tumors, of which 40 belonged to the luminal A subgroup and the remaining 4 to the HER2 group. This

difference was not statistically significant. However, if only those tumors with more than 10% reactive tumor cells (a usual cut-off in immunohistochemistry) was considered, 12/45

(27%) positive tumors in the "basal" group, versus only 3 (7%) in the control group were found, and the difference became statistically significant ($p=0.02$). In any case, the proportion of CK5/6-expressing tumors in the basal group was much lower than expected.

Discussion

This is the first study of molecular subgroups of breast cancer belonging to a single histological type and a single T status. Unfortunately, useful survival curves for the different subgroups could not be calculated due to the small size of the tumors and hence their inherent better initial prognosis, which would make an extremely long follow-up necessary to disclose statistically significant differences in survival and the fact that many patients chose to be followed-up at their local hospital after being operated upon at our center, so that they were lost to the study. However, the correlation with the tested biological and clinical parameters reflected the relative aggressiveness of the tumors belonging to the different subgroups. In this sense, our data were similar to those reported by Carey *et al.* (4) for their cohort of non-African American women in that 72.5% of the tumors belonged to the luminal A variety, which are the ones with the best inherent prognosis, most likely to respond to hormonal therapy and less likely to respond to chemotherapy. Conversely, 13% were triple-negative ("basal-like"), with the worst inherent prognosis, and paradoxically most likely to respond to chemotherapy (7). Carey *et al.* (4) found the "basal" type to be significantly associated with p53 mutation status, mitotic index, nuclear pleomorphism and higher histological grade, exactly as the present study. However, our associations were much more clear-cut, probably due to restriction to the ductal infiltrating type. In fact, every subgroup in our series stood out significantly in the statistical analysis if compared to the rest of tumors, and not only by comparing extremes, such as luminal A vs. "basal-like" tumors as in the Carey *et al.* study (4). An additional interesting finding was that mutant p53 expression was significantly higher in the "basal like" group than in the luminal A group (35% vs. 6%), but was even higher in the pure HER2 group (60%). This may have clinical implications, since HER2+/hormone-receptor-negative tumors are by definition only amenable to chemotherapeutic treatment (besides surgery), and p53 is a major factor in the molecular mechanisms of resistance to chemotherapy, a problem recently addressed by Sorlie *et al.* (8) when studying chemotherapy response rates in relationship to gene expression profiles.

From a practical point of view, our approach defines three distinct subgroups, which are candidates for different clinical management: the luminal A subtype, with an excellent prognosis and responsive to the best existing medical treatment of breast cancer, which is hormonal therapy; the

HER2-expressing subtype, which could eventually benefit from the addition of Trastuzumab to the treatment regimen and finally the triple-negative, "basal-like" subtype, where chemotherapy is the only option. One striking feature was that none of these subgroups correlated with the most important prognostic factor to date, axillary nodal invasion, a feature that already stood out in the seminal reports by Perou *et al.* (1) and van't Veer *et al.* (2), and in all subsequent reports on the same subject. Thus, if treatment strategies in the future are guided mainly by gene expression patterns and not by nodal status as is currently the case, this will constitute a fundamental paradigm shift in the management of breast cancer

Studies of the other, less frequent histological varieties of breast cancer, are mandatory in order to disclose which precise gene-expression pattern defines similar subgroups.

References

- 1 Perou CM, Sørli T, Eisen MB, van de Rijn M, Jeffrey SS, Rees CA, Pollack JR, Ross DT, Johnsen H, Akslen LA, Fluge O, Pergamenschikov A, Williams C, Zhu SX, Lonning PE, Borresen-Dale AL, Brown PO and Botstein D: Molecular portraits of human tumours. *Nature* 406: 747-752, 2000.
- 2 van't Veer LJ, Dai H, van de Vijver MJ, He YD, Hart AA, Mao M, Meterse HL, van der Kooy K, Marton MJ, Witteveen AT, Schreiber GJ, Kerkhoven RM and Roberts C: Gene expression profiling predicts clinical outcome of breast cancer. *Nature* 415: 530-536, 2002.
- 3 Sørli T: Molecular portraits of breast cancer: tumor subtypes as distinct disease entities. *Eur J Cancer* 40: 2667-2675, 2004.
- 4 Carey LA, Perou CM, Livasy CA, Dressler LG, Cowan D, Conway K, Karaca G, Troester MA, Tse CK, Edmiston S, Deming SL, Geradts J, Cheang MC, Nielsen TO, Moorman PG, Earp HS and Millikan RC: Race, breast cancer subtypes, and survival in the Carolina Breast cancer study. *JAMA* 295: 2492-2502, 2006.
- 5 Nunez-Villar MJ, Martinez-Arribas F, Pollan M, Lucas AR, Sanchez J, Tejerina A and Schneider J: Elevated mammaglobin (h-MAM) expression in breast cancer is associated with clinical and biological features defining a less aggressive tumour phenotype. *Breast Cancer Res* 5: R65-70, 2003.
- 6 Schneider J, Pollan M, Tejerina A, Sanchez J and Lucas AR: Accumulation of uPA-PAI-1 complexes inside the tumour cells is associated with axillary nodal invasion in progesterone-receptor-positive early breast cancer. *Br J Cancer* 88: 96-101, 2003.
- 7 Carey LA, Dees EC, Sawyer L, Gatti L, Moore DT, Collicchio F, Ollila DW, Sartor CI, Graham ML and Perou CM: The triple-negative paradox: primary tumor chemosensitivity of breast cancer subtypes. *Clin Cancer Res* 13: 2329-2334, 2007.
- 8 Sorlie T, Perou CM, Fan C, Geisler S, Aas T, Nobel A, Anker G, Akslen LA, Botstein D, Borresen-Dale AL and Lonning PE: Gene expression profiles do not consistently predict the clinical treatment response in locally advanced breast cancer. *Mol Cancer Ther* 5: 2194-2198, 2006.

Received July 10, 2007

Accepted August 27, 2007